

Recurrent Pleural Effusion Secondary to Erythrodermic Psoriasis Following Cardiac Surgery: A Unique Diagnostic Challenge

Keeran Mahendra Kumar¹, Maria Comanici², Shahzad G. Raja^{3*}

¹Faculty of Medicine, Imperial College London.

Email: keeranm097@gmail.com

²Department of Cardiac Surgery, Harefield Hospital, London, United Kingdom.

Email: maria.comanici9@gmail.com

³Department of Cardiac Surgery, Harefield Hospital, London, United Kingdom.

Email: drsgraja@gmail.com

Abstract

Pleural effusion can complicate cardiac surgery, posing diagnostic and management challenges. We present the case of a 77-year-old male with recurrent pleural effusions following cardiac surgery and an exacerbation of erythrodermic psoriasis. Despite thorough investigation, including serial thoracentesis, the underlying cause remained elusive. While some psoriasis-related complications such as psoriasis-associated aseptic pneumonitis or capillary leak syndrome were considered, they did not fully align with the clinical presentation. This unique case underscores the complexity of managing post-operative pleural effusion, especially in conjunction with uncommon dermatological conditions like erythrodermic psoriasis, highlighting the importance of multidisciplinary collaboration and tailored therapeutic approaches.

Keywords: Coronary Artery Bypass Grafting, Erythrodermic Psoriasis, Psoriasis, Recurrent Pleural Effusion, Thoracentesis.

INTRODUCTION

Pleural effusion is a recognized complication following cardiac surgery, often resulting from a variety of underlying causes such as infection, inflammation, trauma, fluid overload, or impaired lymphatic drainage.^[1] While the management of pleural effusion typically involves addressing the primary cause and alleviating symptoms through diuretics, pain control, and chest drainage, the presence of uncommon coexisting conditions can complicate the diagnostic process and treatment approach.^[1]

In this case report, we present a unique and challenging scenario of recurrent pleural effusion secondary to erythrodermic psoriasis following cardiac surgery. Erythrodermic psoriasis, a severe and rare form of psoriasis characterized by widespread erythema and scaling, can significantly impact the patient's overall health, and complicate the clinical picture.^[2] The coexistence of this dermatological condition with post-operative pleural effusion poses a diagnostic dilemma, as it necessitates a thorough evaluation to distinguish between potential causes and to formulate an effective treatment plan.

This case underscores the importance of considering uncommon coexisting conditions in patients with pleural

effusion post-cardiac surgery, highlighting the need for a multidisciplinary approach to accurately diagnose and manage such complex cases. Through this report, we aim to contribute to the existing body of knowledge and provide insights into the challenges and considerations involved in managing pleural effusion in the context of erythrodermic psoriasis. This case is being reported in line with the SCARE 2023 criteria.^[3]

CASE PRESENTATION

A 77-year-old male was diagnosed with severe aortic stenosis and severe stenosis in proximal right coronary artery. The patient had a past medical history of eczema and psoriasis and was an ex-smoker. He underwent an aortic valve replacement with bioprosthetic valve and coronary artery bypass grafting using the long saphenous vein. Following surgery, the patient was haemodynamically stable, had an uncomplicated recovery and discharged from the hospital after 6 days.

***Correspondence:** Department of Cardiac Surgery, Harefield Hospital, London, United Kingdom
Email: drsgraja@gmail.com

Submitted: 08th May, 2024

Received: 24th May, 2024

Accepted: 01st July, 2024

Published: 05th July, 2024

Access This Article Online

Quick Response Code:



Website:
<https://jcrms.com>

How to Cite This Article: Kumar KM, Comanici M, Raja SG. Recurrent Pleural Effusion Secondary to Erythrodermic Psoriasis Following Cardiac Surgery: A Unique Diagnostic Challenge. J Case Rep Med Stud Train. 2024;1(2):2-5

Six weeks following the operation, the patient presented with moderate breathlessness and a new rash across the right side of his body. A large right-sided pleural effusion was noted on ultrasound scan (USS) and 1500mls of straw-coloured fluid was aspirated under USS guidance at his local district general hospital. Biochemical analysis of the pleural fluid confirmed it to be transudate.

Two weeks following the pleural fluid aspiration, the patient was re-admitted to his district general hospital with recurrent large right-sided pleural effusion. Whilst in hospital, an echocardiogram revealed normally functioning bioprosthetic valve with preserved ejection fraction. On admission, the patient also had peripheral oedema, reduced peripheral perfusion, and a persistent generalised erythematous rash. The serum albumin on admission was 18 g/L (normal range 34-54 g/L). Upon consultation with dermatology, a diagnosis of acute flare up of psoriasis with erythroderma was proposed and a punch biopsy of the skin was performed. Following the skin biopsy the patient was prescribed the greasy emollient 50:50, 3-4 times a day, and steroid ointment Betnovate RD to all red flaky areas twice a day about 1 hour after the greasy moisturiser. Acitretin 25mg once daily, an oral retinoid, was also prescribed. A separate consultation with the respiratory team for recurrent pleural effusion resulted in a diagnosis of reactive postoperative pleural effusion and the patient was transferred to our tertiary cardiothoracic hospital for video assisted thoracoscopic drainage which the patient declined. A chest drain was inserted and a

further 1500 mls of transudate effusion was drained. The skin biopsy was reported as showing patchy mild hyper and parakeratosis with mild acanthosis. Psoriasiform hyperplasia was not seen. There was moderate upper dermal perivascular chronic inflammation present. This was composed of lymphocytes and very occasional plasma cells and eosinophils. Occasional focus of spongiosis and exocytosis was noted. Some red blood cell extravasation was noted. A fungal stain was negative. Histological features of psoriasis or mycosis fungoides/Sezary syndrome were not seen. Also, classical features of pityriasis rubra pilaris were not seen. However, this possibility could not be completely excluded. Changes were subtle spongiform and may be drug related. There was no evidence of malignancy. A diagnosis of spongiform dermatitis was suggested. It was proposed that his erythrodermic state resulted in low albumin and was the likely cause of his resistant peripheral oedema and fluid overload. Skin barrier support and inflammation improvement with time were proposed to improve the component of the low albumin related to his skin disease. The patient was also commenced on bumetanide 1 mg once daily and spironolactone once daily. The chest drain was removed after 10 days. The patient was recalled after 10 days for a repeat chest x-ray and there was minimal pleural effusion (Figure 1). The erythroderma and skin inflammation also improved with concomitant improvement in serum albumin level to 28 g/L two weeks post-discharge.

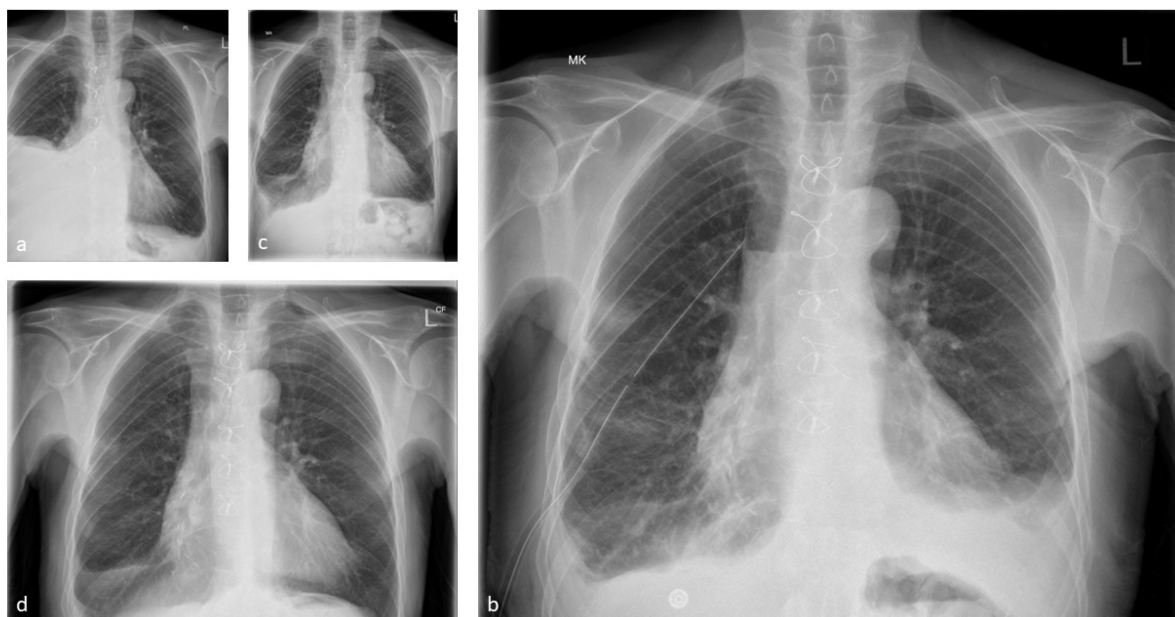


Figure 1: (a) Chest X-ray on Transfer to Tertiary Cardiothoracic Unit. (b) Chest X-ray after Chest Drain Insertion. (c) Chest Drain Post-drain Removal. (d) Chest Drain 10 Days after Discharge.

DISCUSSION

Pleural effusion is a common complication following cardiac surgery, the vast majority occurring within 28 days of surgery.^[4] Approximately a third of patients were found

to develop a pleural effusion during their post-operative recovery.^[5] In a prospective case series involving 389 patients assessed 28 days post-cardiac surgery, findings indicated that 66.67% of individuals developed pleural

effusion following Coronary Artery Bypass Grafting (CABG), 62% experienced effusion after undergoing both CABG and valve surgery, and 45% exhibited effusion after valve surgery alone. Pleural effusions which manifest more than 28 days after surgery are more likely to be large (an effusion that occupies more than 25 percent of the hemithorax) and clinically significant than effusions which appear within 28 days of surgery.^[6]

Pleural effusions that are asymptomatic and small (occupying less than 25% of the hemithorax) should be monitored clinically and radiologically but not typically treated. Most small pleural effusions resolve spontaneously within two to six weeks however they may persist for multiple months following surgery.^[7] The mainstay of treatment for large, symptomatic pleural effusion is therapeutic thoracentesis under ultrasound guidance. This aims to reduce the size of effusion and allows for pleural fluid analysis. In the case of recurrent pleural effusion without a specific underlying aetiology, serial thoracentesis can be performed in addition to trialling oral glucocorticoids. Indwelling pleural catheters are another therapeutic option, which have shown efficacy in managing recurrent pleural effusions.^[8]

Psoriasis is typically a chronic condition with acute flare-ups of disease and not associated with severe complications if managed well. Some forms of psoriasis, notably erythrodermic and pustular psoriasis are associated with more life-threatening complications.^[9] A few cases of psoriasis-associated aseptic pneumonitis (PAAP) have been reported in patients with pustular or erythrodermic psoriasis.^[10,11] PAAP in these reports was characterised by sudden respiratory deterioration with tachypnoea, arterial hypoxaemia, and elevated neutrophil count. This deterioration occurs alongside a skin flare-up. Radiological findings include bilateral interstitial infiltration and alveolar changes.^[10,11] Whilst the patient in this report may loosely fit the clinical vignette of PAAP, pleural effusion has never been previously mentioned as a feature, so it is unlikely to be the diagnosis.

Patients taking acitretin for psoriasis have been reported to develop capillary leak syndrome.^[12] In these reports, patients develop oedema, pleural effusion, and dyspnoea. However, it is unlikely this is the cause of the pleural effusion in the case of this patient as he began acitretin treatment after developing peripheral oedema, pleural effusion, and shortness of breath.

The incongruity between the clinical skin presentation and biopsy findings added a layer of complexity to the case. Clinically, the patient's skin exhibited a generalized erythematous rash, suggesting a severe flare-up of erythrodermic psoriasis. However, the skin biopsy results did not confirm this diagnosis, showing only patchy mild hyper and parakeratosis with mild acanthosis, without psoriasiform hyperplasia, which is typically seen in psoriasis. Instead, the biopsy revealed moderate upper dermal perivascular chronic inflammation, occasional spongiosis, and exocytosis, which were not definitive for psoriasis. This discrepancy necessitated consideration of other potential diagnoses, making it more

challenging to develop a clear and effective treatment plan. Despite the lack of definitive biopsy confirmation, the clinical presentation of erythrodermic psoriasis was still considered a significant contributing factor to the patient's condition, particularly in relation to the low albumin levels, peripheral oedema, and fluid overload. This case highlights the importance of integrating clinical findings with histopathological results to arrive at a comprehensive diagnosis and treatment strategy. The underlying cause of the patient's condition in the case report remains unclear, but a possible association with erythrodermic psoriasis is the most likely explanation.

CONCLUSION

In summary, this case involves a post-operative patient following aortic valve replacement with erythrodermic psoriasis who experienced recurrent pleural effusion. Despite multiple thoracenteses, the effusion persisted until the erythrodermic psoriasis improved, leading to its resolution. This case is unique as it does not align with previously documented pulmonary psoriasis complications, such as PAAP or capillary leak syndrome, making it both distinctive and challenging to interpret.

FUNDING

No funding was received.

CONFLICT OF INTEREST

All the authors have no actual or potential conflicts of interest to declare.

REFERENCES

1. Feller-Kopman D, Light R. Pleural Disease. *N Engl J Med*. 2018; 378(8): 740-51. doi: <https://doi.org/10.1056/nejmra1403503>.
2. Menter A, Griffiths CE, Tebbey PW, Horn EJ, Sterry W. Exploring the association between cardiovascular and other disease-related risk factors in the psoriasis population: the need for increased understanding across the medical community. *J Eur Acad Dermatol Venereol*. 2010; 24(12): 1371-7. doi: <https://doi.org/10.1111/j.1468-3083.2010.03656.x>.
3. Sohrabi C, Mathew G, Maria N, Kerwan A, Franchi T, Agha RA. The SCARE 2023 guideline: updating consensus Surgical CAse REport (SCARE) guidelines. *Int J Surg*. 2023; 109(5): 1136-40. doi: <https://doi.org/10.1097/js9.0000000000000373>.
4. Kollef MH. Chronic pleural effusion following coronary artery revascularization with the internal mammary artery. *Chest*. 1990; 97(3): 750-1. doi: <https://doi.org/10.1378/chest.97.3.750>.
5. Gilbert CR, Porcel JM. Management of recurrent transudative pleural effusions: can we REDUCE unnecessary interventions? *Eur Respir J*. 2022; 59(2): 2101942. doi: <https://doi.org/10.1183/13993003.01942-2021>.
6. Light RW, Rogers JT, Moyers JP, et al. Prevalence and clinical course of pleural effusions at 30 days after coronary artery and cardiac surgery. *Am J Respir Crit Care Med*. 2002; 166(12 Pt 1): 1567-71. doi: <https://doi.org/10.1164/rccm.200203-184oc>.

7. Bhatnagar R, Maskell N. The modern diagnosis and management of pleural effusions. *Bmj*. 2015; 351: h4520. doi: <https://doi.org/10.1136/bmj.h4520>.
8. Ajmani G, Ravikumar N, Wagh A. Management strategies for recurrent pleural effusion: a clinical practice review. *AME Med J*. 2023; 8: 35. doi: <https://doi.org/10.21037/amj-23-107>.
9. Tran M, Lea V, Wong LC. Complications of psoriasis: clinicopathology, screening, and management. *Br J Gen Pract*. 2024; 74(744): 329-30. doi: <https://doi.org/10.3399/bjgp24x738753>.
10. Noure L, Küçük K, Simeni Njonnou SR, Del Marmol V, White JM, Bondue B. Respiratory Distress Syndrome Associated with Erythrodermic Psoriasis. *Case Rep Dermatol*. 2021; 13(1): 83-88. doi: <https://doi.org/10.1159/000511368>.
11. Kluger N, Bessis D, Guillot B, Girard C. Acute respiratory distress syndrome complicating generalized pustular psoriasis (psoriasis-associated aseptic pneumonitis). *J Am Acad Dermatol*. 2011; 64(6): 1154-8. doi: <https://doi.org/10.1016/j.jaad.2009.11.022>.
12. Ezine E, Pedailles S, Domp martin A, Morice C. [Acitretin-induced capillary leak syndrome: Case report and literature review]. *Ann Dermatol Venereol*. 2020; 147(8-9): 535-41. doi: <https://doi.org/10.1016/j.annder.2020.04.021>.